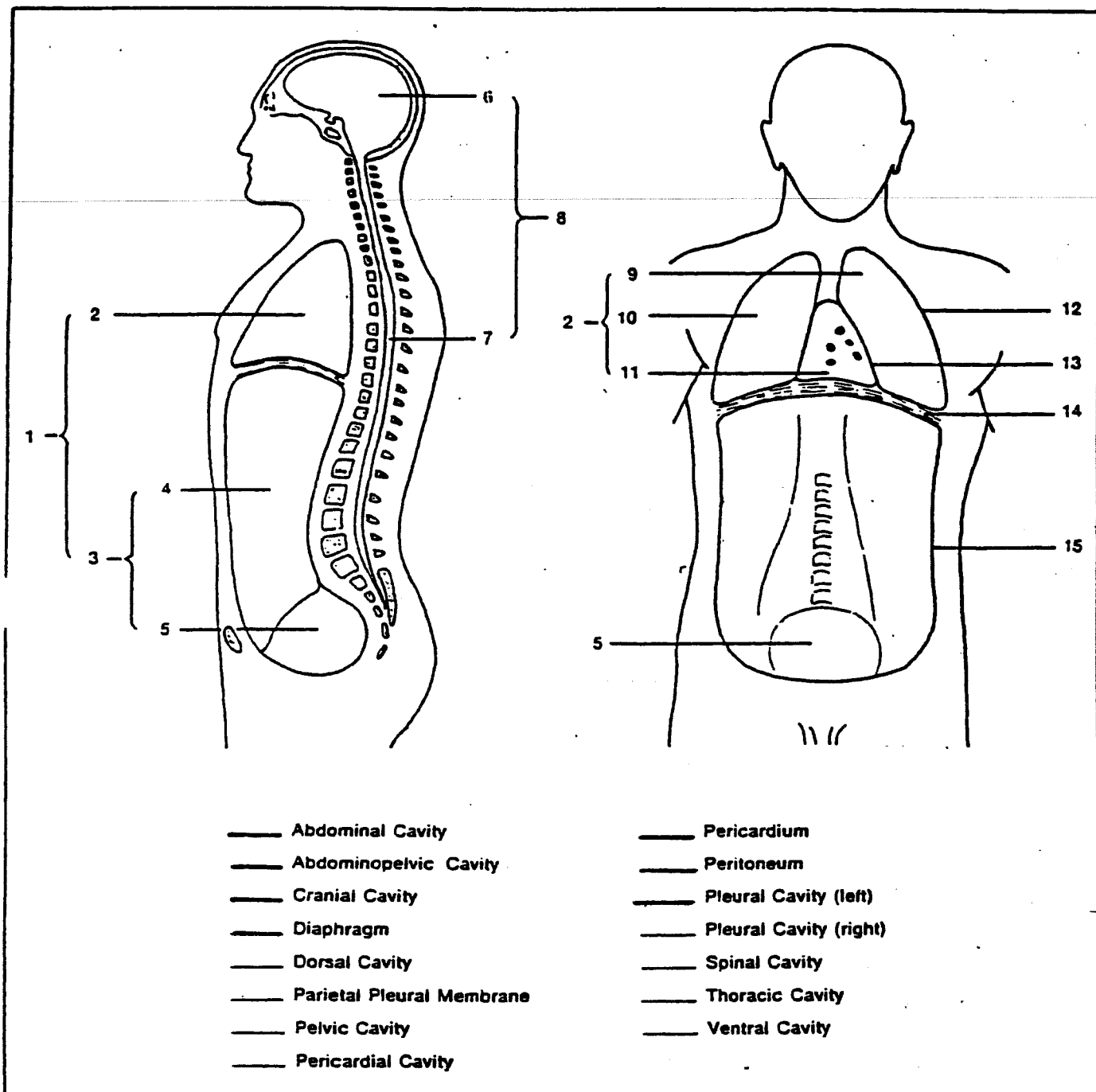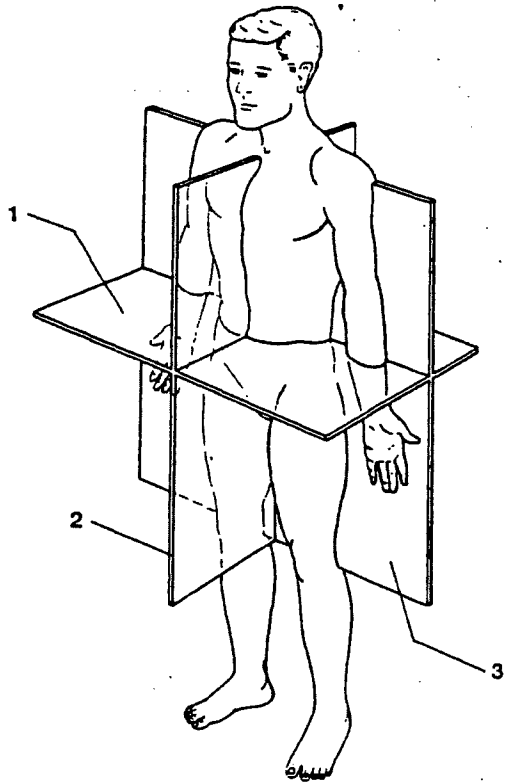


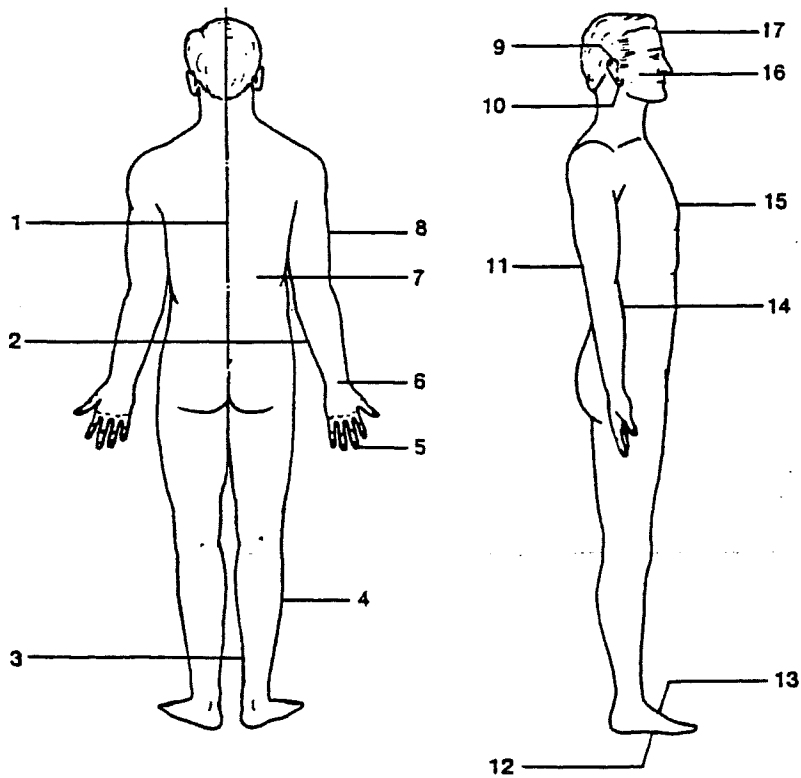
Figure 1-6 Body Cavities

Figure 1-2 Body Sections



- Midsagittal Section
- Frontal Section
- Transverse Section

Figure 1-3 Body Surfaces



- Median Line
- Ventral Surface of Trunk
- Dorsal Surface of Trunk
- Anterior Surface of Head
- Lateral Surface of Head
- Superior Portion of Ear
- Inferior Surface of Ear
- Anterior Surface of Arm
- Posterior Surface of Arm
- Lateral Surface of Arm
- Medial Surface of Arm
- Proximal Portion of Hand
- Distal Portion of Hand
- Lateral Surface of Leg
- Medial Surface of Leg
- Superior Surface of Foot
- Inferior Surface of Foot